

Proofs of CID 5727

=====

Dear Author:

The proof of your article to be published by Elsevier Science in Clinics in Dermatology can be viewed from:

<http://rapidproof.cadmus.com/RapidProof/retrieval/index.jsp>

Login: your e-mail address

Password: ----

This file contains a PDF proof of your complete article, a list of author queries, and a guide to proofreader's marks. For helpful information on PDF files, please see the section Reading PDF Documents at the end of this e-mail.

If, after reading this message, you would prefer to receive paper proof of your article or any color figures, please inform us immediately by replying to this e-mail with full mailing details.

Please use this proof solely for checking typesetting, editing, and the completeness and correctness of the text, tables, and figures. Any significant changes to the article as accepted must be approved by the editorial office. Also, make sure you answer any questions that appear on the list of author queries.

Please respond with your corrections within 48 hours to the address below (if you have no corrections, please inform us) by one of the following means:

- * Send an e-mail message to the journal production editor (listed below; please note this is not the journal editor) with approval to proceed or a brief summary of the corrections to be made;
- * Print out the list of author queries, write your answers to the queries on the printout, and fax the page to the journal production editor (alternatively, you can type the author queries and your answers in an e-mail message to the journal production editor); or
- * Print out the PDF of your proofs, indicate any corrections in the margins of the proofs (using a black pen), and fax or mail the proofs to the journal production editor.

If there are any significant concerns about the quality of the proofs (in terms of figure layout, setting of equations, etc.), please detail these concerns in a separate letter accompanying your faxed or e-mailed corrections. The journal production editor will ensure your concerns are addressed.

If you submitted usable colour figures with your article they will appear in colour on the web, at no extra charge, as you can see in the attached PDF proof of your article. In the printed issue, colour reproduction depends on journal policy and whether or not you agree to bear any costs.

Do not attempt to edit the PDF file electronically (including adding post-it type notes); such corrections cannot be accepted at this time. Instead, please submit your corrections by one of the three means detailed above. You should have already received and returned a copyright transfer or short license agreement and an offprint order form. If you have not yet returned them, please fax, and follow by mail, the signed forms. We must have the original signed copyright transfer or short license agreement to publish your article.

Reading PDF Documents

To view and print your article, you will need Acrobat Reader from Adobe. This program is freely available and can be downloaded from www.adobe.com. Note that this reader is available for a whole series of platforms, which include PC, Mac, and Unix.

There are some points that you should consider:

- * Any gray halftones or color figures are best viewed on screen, where they are optimized. If you have instructed us to reproduce your artwork in color, it should be displayed as such in this PDF proof.
- * If you are unable to see color, check that the Display large images tickbox under File/Preferences/General is ticked. If you are still unable to view your color, please contact us immediately.
- * If you print the PDF file and notice nonstandard output, check if the problem is also present on screen. If the correct printer drive is not installed on your PC, the printer output will be distorted.

Finally, may I thank you in anticipation of your prompt cooperation and for publishing your article in Clinics in Dermatology.

Kind regards,

Ms. Cathy Yake
Issue Manager
Cadmus Professional Communications
Airport Square 7
940 Elkridge Landing Road
Linthicum, MD 21090
Ph: 410-694-4140
Fx: 410 691-6235
E: yakec@cadmus.com

Proofreader's Marks

MARK	EXPLANATION	EXAMPLE
	TAKE OUT CHARACTER INDICATED	Your proof.
^	LEFT OUT, INSERT	u [^] Your proof.
#	INSERT SPACE	# Your proof. [^]
9	TURN INVERTED LETTER	Your p [^] roof.
X	BROKEN LETTER	X Your p [^] rof.
^{vv} eq#	EVEN SPACE	eq# A good proof.
○	CLOSE UP: NO SPACE	Your pro [^] gf.
tr	TRANSPOSE	tr A proof [^] good
wf	WRONG FONT	wf Your proof.
lc	LOWER CASE	lc Your proof.
≡ caps	CAPITALS	Your proof. caps Your proof.
ital	ITALIC	Your proof. ital Your proof.
rom	ROMAN, NON ITALIC	rom Your proof.
bf	BOLD FACE	Your proof. bf Your proof.
..... stet	LET IT STAND	Your proof. stet Your proof.
out sc.	DELETE, SEE COPY	out sc. She Our proof. ^
spell out	SPELL OUT	spell out Queen (Eliz.)
#	START PARAGRAPH	# read. [Your
no #	NO PARAGRAPH: RUN IN	no # marked. → # Your proof.
└	LOWER	└ [Your proof.]

MARK	EXPLANATION	EXAMPLE
┌	RAISE	┌ [Your proof.]
┐	MOVE LEFT	┐ Your proof.
└	MOVE RIGHT	└ Your proof.
	ALIGN TYPE	┐ Three dogs. Two horses.
==	STRAIGHTEN LINE	== Your p [^] roof.
⊙	INSERT PERIOD	⊙ Your proof. [^]
;/	INSERT COMMA	;/ Your proof. [^]
:/	INSERT COLON	:/ Your proof. [^]
;/	INSERT SEMICOLON	;/ Your proof. [^]
∨	INSERT APOSTROPHE	∨ Your m [^] ans proof.
∨∨	INSERT QUOTATION MARKS	∨∨ Marked it proof. [^]
=/	INSERT HYPHEN	=/ A proofmark. [^]
!	INSERT EXCLAMATION MARK	! Prove it. [^]
?	INSERT QUESTION MARK	? Is it right. [^]
Ⓢ	QUERY FOR AUTHOR	Ⓢ was Your proof read by. [^]
[/]	INSERT BRACKETS	[/] The Smith girl. ^ ^
(/)	INSERT PARENTHESES	(/) Your proof. [^]
1/m	INSERT 1-EM DASH	1/m Your proof. [^]
□	INDENT 1 EM	□ Your proof
▢	INDENT 2 EMS	▢ Your proof.
▣	INDENT 3 EMS	▣ Your proof.



Changing Paradigms in Dermatology: Confocal Microscopy in Clinical and Surgical Dermatology

SALVADOR GONZÁLEZ, MD, PhD
KIRSTY SWINDELLS, MD
MILIND RAJADHYAKSHA, PhD
ABEL TORRES, MD

Abstract. *The current practice of pathology and dermatopathology depends upon the evaluation of tissue in some manner extirpated from the patient and then processed and stained. While high resolution of detail can be accomplished by this method, there are certain risks and disadvantages. Recent imaging techniques now allow for a potential of achieving noninvasive high-resolution analysis of lesions in situ in the patient. Of these, Reflectance mode confocal microscopy offers the highest resolution imaging comparable to routine histology. Being entirely non invasive, skin can be observed in its native, dynamic state. This chapter will review the fundamentals of in vivo confocal imaging and the clinical applications in general and surgical dermatology.*

The approach to diagnosis of many skin conditions today usually depends on the histopathological microscopic analysis of excised and processed tissue. The latter is a well established technique that provides high-resolution cellular and subcellular tissue detail. It requires, however, that a biopsy be performed, which can be painful, time-consuming, costly, only provides information on the excised tissue examined, and carries a potential risk of scarring and infection. It also typically requires processing and staining of the specimen, which may induce artifacts.

Recent advances in imaging techniques provide the potential for noninvasive high-resolution skin imaging in vivo. These can overcome some of the disadvantages of the biopsy and histologic analysis. Such advances include optical coherence tomography,¹ high-frequency ultrasound,² magnetic resonance imaging,³ and reflectance confocal microscopy (RCM).⁴⁻⁶ Of these, RCM offers the highest resolution imaging comparable to routine histology.

Principles of Reflectance-Mode Confocal Microscopy

The confocal scanning microscope was invented by Marvin Minsky while working as a postdoctoral fellow at Harvard in 1955.⁷ However, it required the development of light source and computerization technologies to enable realization of tissue imaging in vivo. Since the 1980s several research groups have demonstrated the use of tandem scanning confocal microscopy for imaging human and animal tissue in vivo.⁸⁻¹¹ Confocal scanning laser microscopy for imaging human skin in vivo was first reported in 1995.⁶ In vivo RCM offers several important advantages over conventional histology. Imaging is painless and noninvasive, causing no tissue damage. The skin is not altered in any way by processing or staining, minimizing artifact. The data, collected in real time, is faster than routine histology, and the skin site can be repeatedly imaged over time to evaluate dynamic changes such as response to therapy.¹²⁻¹⁶

The principle of reflectance confocal microscopy involves the use of a point source of light that illuminates a small spot within tissue. The reflected light (reflectance) is then imaged onto a detector after passing through a small pinhole. The pinhole prevents out-of-focus light from reaching the detector. This means that only the region of the specimen that is in focus (confocal) is detected (Fig 1). To create an image of the whole plane of the sample being studied, the point source beam is scanned. This enables a virtual sectioning of a thin horizontal tissue plane (microscopy) in vivo. The

From the Department of Dermatology, Wellman Laboratories of Photomedicine, Massachusetts General Hospital, Harvard Medical School, Boston, Massachusetts and the Division of Dermatology, Loma Linda University Hospital, Loma Linda, California.

Address reprint requests to Salvador González, MD, PhD, Wellman Laboratories of Photomedicine, BAR 814, Department of Dermatology, 50 Blossom Street, Boston MA 02114.

E-mail address: sgonzalez@partners.org

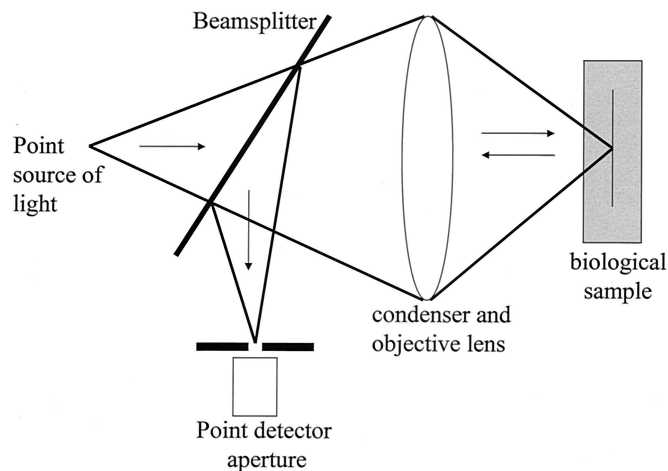


Figure 1. Scheme of a reflectance mode confocal microscope illustrating noninvasive imaging of a thin (focused) plane of skin. Back-scattered light is detected from the skin rather than transmitted light. The small aperture (pinhole) in front of the detector collects only the light in focus, while rejecting light that is out of focus.

resolution provided by RCM depends on the pinhole size, the numerical aperture of the objective lens, and the wavelength used. Lasers of different wavelengths may be used as the light source for reflectance confocal microscopy. Longer wavelengths penetrate deeper into the skin but provide less lateral resolution. Back-scattering of light occurs due to local variations of the refractive index within the tissue as well as when the scattering structure has a size similar to the illuminating wavelength. Near-infrared wavelengths (800-1064 nm), such as those used in our laboratories, produce strong back-scattering from melanosomes, despite melanin absorption at this wavelength, because they have a high refractive index relative to the surrounding epidermis and have a size similar to the illuminating wavelength. This means that cells containing melanin, such as basal keratinocytes and melanocytes, image brightly. Also, more contrast is obtained where the skin being imaged has a darker color or is a pigmented lesion.

The commercially available RCM that we use has a wavelength of 830 nm and 30 \times objective lens of NA 0.9, which provides a lateral resolution of approximately 1 μ m and an axial resolution (section thickness) of 3-5 μ m. With this system, it is possible to image normal skin to a depth of 200-250 μ m. This is sufficient for imaging epidermis and upper dermis (papillary dermis and upper reticular dermis). Imaging deeper layers within the skin can also be achieved by using greater laser power, but the laser power used in the commercially available device is less than 30 mW and causes no tissue damage or eye injury. Water immersion lenses are used since the refractive index of water (1.33) is close to that of epidermis (1.34) and this minimizes spherical aberrations caused when the light passes

through the tissue-air interface. It is also possible to use water-based gels as immersion media, particularly if imaging a scaly or hyperkeratotic lesion since the gel settles between disrupted corneocytes, reducing irregularities in refraction.¹² Gel is also useful if imaging a skin site that is not particularly flat, since the gel doesn't run off of the skin in the same way water can. A skin contact device is used to reduce motion artifact and contain the water or gel interface when imaging.¹² This device consists of a metal ring that is fixed to the patient's skin with adhesive, and is coupled to the microscope housing with a magnet during imaging. It has a concave shape to hold the immersion medium. By moving the objective lens in the z (vertical) plane with respect to the skin, it is possible to image at different horizontal levels within the tissue since the focal plane is progressively moved deeper. Images can be "grabbed" to produce static pictures of horizontal skin sections as well as recorded on videotape (20-30 Hz) to produce movies to demonstrate dynamic events such as blood flow.^{6,12-16}

Reflectance Confocal Microscopy Findings of Normal Skin

To appreciate and interpret images from abnormal skin, one must be familiar with the appearance of images from normal skin.^{6,12} Two differences from routine histology are that the images obtained are horizontal or *en face*, similar to Mohs surgery horizontal sections rather than the vertical sections that are normally obtained from routine histology, and they are gray-scale images similar to radiographs. The field of view with RCM varies with different microscopes, but is generally 250-500 μ m across. The level being imaged can be ascertained by the morphologic appearance of tissue at a given depth or by measuring the depth of the section, using a micrometer attached to the z stage of the objective lens.

When imaging the skin in real time starting from the surface and progressing deeper, the most superficial images obtained are of the stratum corneum. This produces very bright (almost whitewashed) images because the refractive difference at the interface between the immersion medium (for example, water at 1.33) and the stratum corneum (1.54) results in a large amount of back-scattered light. Low laser fluences help to minimize this. The morphologic appearance is that of anucleated polygonal corneocytes measuring 10-30 μ m in size, and grouped in "islands" separated by skin folds, which appear very dark (Fig 2A). The next layer (section) seen is the stratum granulosum consisting of 2 to 4 layers of cells measuring 25-35 μ m in size. Here the nuclei can be appreciated as dark central ovals within the cell, surrounded by bright grainy cytoplasm (Fig 2B). At 20-100 μ m below the stratum corneum is the

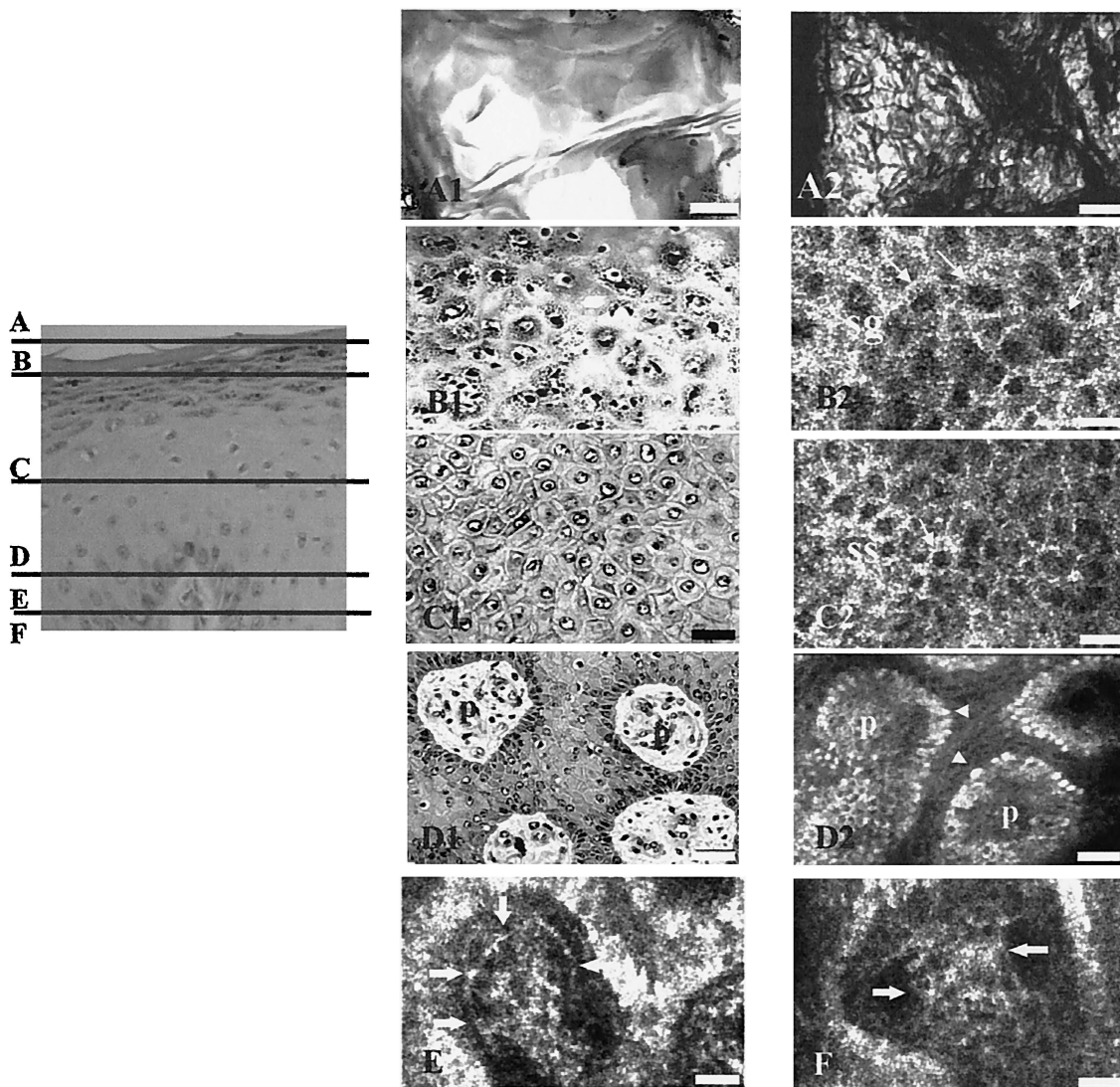


Figure 2. Correlation between vertical and transverse sections (H&E and *in vivo* confocal) of normal skin. In confocal images, the corneocytes appear as bright polygonal shapes (A2, arrows), and are of size 10-30 μm . Granular cells (B2, arrows) are regularly seen at depths of 10-15 μm . The dark oval areas correspond to nuclei within the bright cytoplasm. Spinous keratinocytes (C2, arrows) are seen at 20-100 μm below the stratum corneum. Note that basal keratinocytes (D2, arrows), located around of a dermal papillae (p, D), are brighter than keratinocytes of spinosum (ss, C2) and granulosum layers (sg, B2). Blood vessels (arrows, E) and collagen bundles (arrows, F) are also seen (A1, A2, B1, C1, D1, 40 \times /0.65 NA dry objective lens; B2, C2, D2, E, F, 30 \times /0.9 NA water immersion objective lens; scale bar, 25 μm). Source: Rajadhyaksha M, González S, Zavislan J, et al. *In vivo* confocal scanning laser microscopy of human skin II: advances in instrumentation and comparison to histology. *J Invest Dermatol* 1999;113:293-303. Reprinted by permission of Blackwell Science, Inc.

stratum spinosum. This consists of a tight honeycomb pattern of smaller cells 15-25 μm in size with well-demarcated cell borders (Fig 2C). The deepest layer of epidermis, the basal layer, is seen as bright clusters of cells measuring about 7-10 μm . When imaging a little deeper, the suprapapillary epidermal plate at the dermo-epidermal junction is apparent as rings of bright basal cells surrounding a dark dermal papillae, which often show a central area of blood flow consistent with papillary dermal vascular loops (Fig 2D). The superficial (papillary) dermis can be seen to consist of a network of reticulated fibers and small blood vessels.

Other features that can be observed in normal skin include eccrine ducts, which appear as bright centrally hollow structures that spiral through epidermis and dermis, and hair shafts with pilo-sebaceous units. These appear as whorled centrally hollow structures with elliptical elongated cells at the circumference and a central refractile long hair shaft.

The appearance of normal skin varies according to the skin site and skin color being imaged.¹⁷ For example, skin from sun-exposed or darkly pigmented sites appears generally brighter because of what appears to be more pigment at the basilar layer. Sun-exposed skin

also demonstrates thicker and more fissured or wrinkled stratum corneum, more randomly arranged and irregularly shaped dermal papillae, and clumping of the dermal reticulated pattern, consistent with collagen and elastic fibers. Variation in the density of keratinocytes is also apparent, with sun-protected sites showing a greater density than sun-exposed sites. The palms and soles of the feet are notable for having an extremely thick stratum corneum and a greater number of eccrine ducts.

Reflectance Confocal Microscopy of Non-Neoplastic Skin Lesions

We have used RCM to characterize a number of clinically relevant proliferative and inflammatory skin disorders. This technique appears to be particularly useful for studying the evolution of a particular disease over time as well as response to therapy. With time, it may also prove to be useful for noninvasive diagnosis.

Psoriasis

Psoriasis is a common inflammatory skin condition, and patients often receive a variety of topical or systemic therapies. With the advent of newer immunomodulatory treatments, an objective method of histologic evaluation is desirable. The RCM features of stable psoriasis vulgaris have been characterized and correlated with routine histology.¹⁸ RCM demonstrates the typical features of psoriasis, including parakeratosis, Munro microabscesses, acanthosis, capillary dilation, and papillomatosis. It was also possible to define histologically the boundary or edge of a lesion.¹⁹

Acute Contact Dermatitis

Contact dermatitis is the commonest occupational skin disease. However, the pathogenesis remains incompletely understood, and there are particular gaps in knowledge relating to differentiation of irritant vs. allergic contact dermatitis and variability in susceptibility to irritant contact dermatitis based on skin color. Typical features of contact dermatitis such as spongiosis, microvesicle formation, inflammatory infiltrate and patchy epidermal necrosis have been visualized in real time using RCM²⁰ (Fig 3). It has also been possible to define several features that may enable differentiation of acute irritant vs. allergic contact dermatitis. We have shown that irritant contact dermatitis induced by patch testing with sodium lauryl sulfate is characterized by superficial epidermal changes. These include stratum corneum disruption, with gaps in the surface microtopography, presence of individual corneocytes, and superficial inflammatory infiltrate. These changes developed 24 hours after patch testing, and were sometimes seen even where no clinical response was appreciated. Changes were also accompanied by a large increase in

transepidermal water loss, suggesting that both these methods can provide a valid assessment of barrier function.²¹ This may be of value in the study of and management of irritant and contact dermatitis.

It has been proposed that there are differences in susceptibility to irritant contact dermatitis related to skin color, with black subjects being more resistant to development than white subjects.²²⁻²⁴ We performed a clinical study to examine this with RCM, using 14 healthy volunteers patch tested with different concentrations of sodium lauryl sulfate.²⁵ It was found that irritancy threshold was dose-dependent and related to skin color. RCM could demonstrate microscopic changes even without clinical evidence of irritation. These features included parakeratosis, spongiosis, microvesicle formation and perivascular inflammatory infiltrate.

Infections

Dermatophyte infections including onychomycosis and tinea pedis are common but may be difficult to diagnose because potassium hydroxide preparations may be negative and fungal culture is slow. RCM enables rapid real-time identification of branched hyphae and inflammatory infiltrate in vivo or in vitro on nail clippings or scrapings.^{26,27}

Folliculitis imaged with RCM has shown the presence of pustules, inflammatory infiltrate, spongiosis, and capillary dilation.²⁸

Warts have also been imaged with RCM. We have demonstrated a hyperkeratotic stratum corneum and the presence of multiple highly refractile round structures measuring 20-40 μm in size within the lesion. We hypothesize that these may be keratohyaline granules or perhaps viral particles within infected keratinocytes, based on their size (unpublished observation).

Reflectance Confocal Microscopy of Neoplastic Skin Lesions

RCM characterization of neoplastic lesions is an important area for research, with the potential to aid in the noninvasive diagnosis and management of a variety of skin cancers. With the advent of newer, less invasive, or topical therapies, it is desirable to use a noninvasive diagnostic tool that can allow high-resolution, accurate identification of tumor subtypes and tumor margins, and response to treatment.

Basal Cell Carcinoma

Basal cell carcinomas (BCC) are the commonest skin tumors in man, and RCM characteristics of BCC have been well defined.²⁹ They include the presence of islands of monomorphic tumor cells that are elongated in shape and have nuclei oriented along the same axis, producing a polarized appearance (Fig 4). This polar-

63
64
65
66
67
68
69
70
71
72
73
74
75
76
77
78
79
80
81
82
83
84
85
86
87
88
89
90
91
92
93
94
95
96
97
98
99
100
101
102
103
104
105
106
107
108
109
110
111
112
113
114
115
116
117
118
119
120
121
122

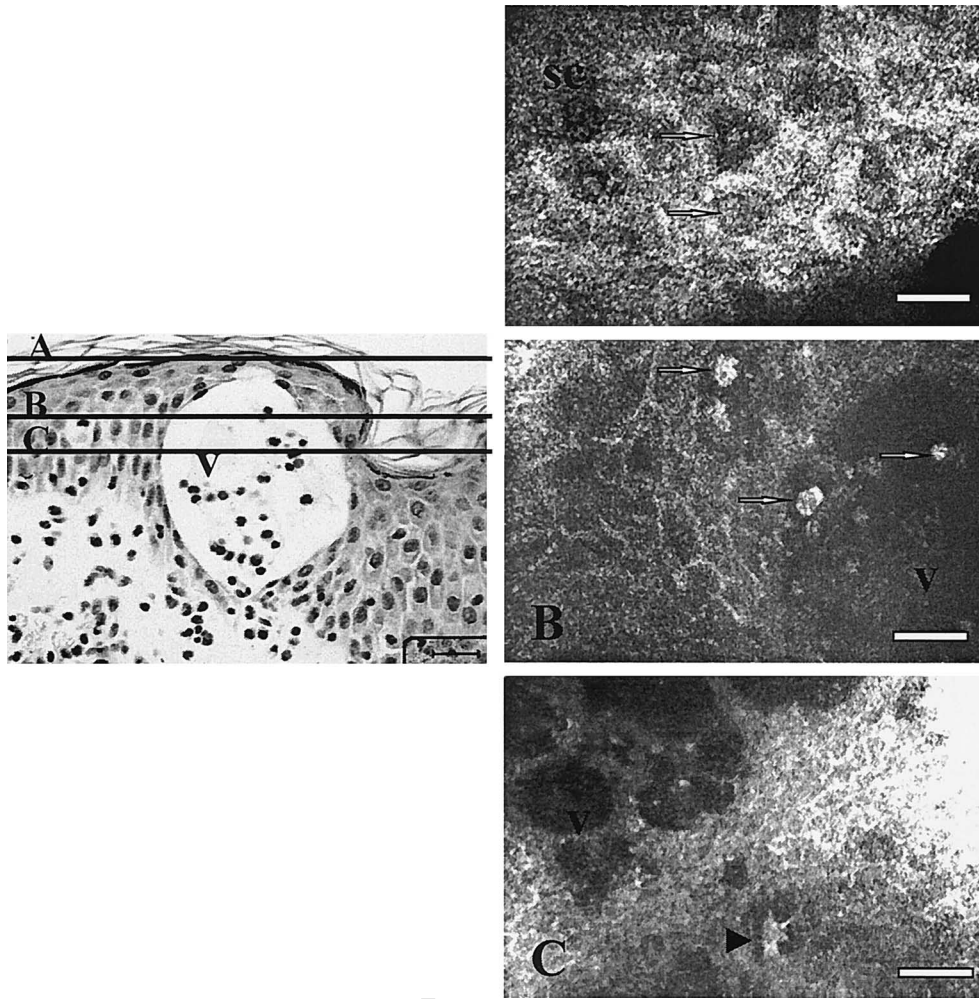


Figure 3. Vertical H&E-stained section of allergic skin reaction 24 hours after removal of Finn chamber (scale bar 25 μm). A, Confocal image of stratum corneum obtained at 24 hours after removal of Finn chamber shows the presence of nuclei (arrows) (100 \times , 1.2 NA water immersion objective lens; scale bar 25 μm). B and C, Confocal images obtained immediately after removal of Finn chamber. Round cells (B, arrows) and dendritic-shaped cells (C, arrow) are clearly seen between keratinocytes or within microvesicles (v). Note dendritic cell in contact with surrounding spinous keratinocytes (B, 100 \times , 1.2 NA water immersion objective lens; scale bar 25 μm ; C, 60 \times , 0.85 NA water immersion objective lens; scale bar 50 μm). Source: González S, González E, White WM, et al. Allergic contact dermatitis: correlation of *in vivo* confocal imaging to routine histology. *J Am Acad Dermatol* 1999;40:708-13. Reprinted by permission of Mosby, Inc.

ized cell pattern persists through the thickness of the epidermis, with loss of the normal progressive size difference of differentiating epidermal cells, loss of the normal honeycomb pattern, and loss of dermal papillae architecture. In addition, pronounced superficial blood vessel prominence, dilation, tortuosity, and rolling of leukocytes along the endothelial wall has been observed. It is also possible to visualize inflammatory cell infiltrate among the tumor cells. We have been participating in a large study evaluating the sensitivity and specificity of RCM features for accurately diagnosing BCC *in vivo*.³⁰ Other areas under investigation include the use of RCM to noninvasively monitor the response to imiquimod, a novel topical immunomodulatory agent.³¹

Actinic Keratoses and Squamous Cell Carcinomas

Actinic keratoses are keratinocytic dysplasias that can develop into squamous cell carcinomas (SCC). The ability to differentiate one from the other would be extremely valuable to rationalize therapeutic options. We have demonstrated the key histopathological features of actinic keratoses using RCM.³² These include architectural disarray, epidermal cell nuclear enlargement with pleomorphism and parakeratosis (Fig 5). It resembles "orderly chaos." However, a limiting factor of RCM is the shallow depth of penetration of the illuminating wavelength, which prevents accurate visualization of the dermo-epidermal junction in particularly hyperkeratotic lesions. This currently restricts the potential of this tool for accurate differentiation of actinic

63
64
65
66
67
68
69
70
71
72
73
74
75
76
77
78
79
80
81
82
83
84
85
86
87
88
89
90
91
92
93
94
95
96
97
98
99
100
101
102
103
104
105
106
107
108
109
110
111
112
113
114
115
116
117
118
119
120
121
122




Figure 4. Confocal images of dysplasia within basal and squamous cell carcinoma. A, Atypical nuclei (arrows) with nonanaplastic pattern that is characteristic of basal cell carcinoma. B, Individual keratinization figures (arrows) within en face anaplastic pattern of a squamous cell carcinoma. (A, 60 \times , 0.85 NA water immersion objective lens. B, 30 \times , 0.9 NA water immersion objective lens; scale bar, 20 μ m). Source: González S, Rajadhyaksha M, Anderson RR. Confocal imaging of benign and malignant proliferative skin lesions in vivo. *Proc SPIE* 1999;3590:59-65. Reprinted by permission of SPIE—The International Society for Optical Engineering.

keratoses vs. squamous cell carcinomas. When not hampered by a parakeratotic, hyperkeratotic lesion, observation of full thickness dysplastic features on RCM is suggestive of SCC. Other changes suggesting SCC, such as vascular patterns and appearance of keratin pearls, are currently being evaluated. A study examining the histopathological response of actinic keratoses to photodynamic therapy over time is ongoing and has been able to demonstrate progressive normalization of architecture in successfully treated lesions.³³ Another study which looks at the ability of RCM to monitor treatment of actinic keratoses with the immune modulator imiquimod is currently ongoing.

Pigmented Lesions

Melanocytic Nevi

RCM is particularly well suited to the imaging of melanocytic lesions, since the large amount of melanin they

possess provides very good contrast. Accurate characterization of the features of benign and malignant melanocytic lesions has important implications for diagnosis and/or screening of pigmented lesions. RCM features of common melanocytic nevi have recently been identified^{34,35} and are typified by the presence of small monomorphous round or oval brightly refractile cells within which nuclei, if visualized, are centrally positioned. In junctional nevi, these cells are seen within the epidermis at the dermo-epidermal junction, typically surrounding dermal papillae (Fig 6A). In compound nevi, on the other hand, cells consistent with nevomelanocytes may be seen at the dermo-epidermal junction but also in the superficial dermis (Fig 6B). These are often grouped in rounded clusters (nests) containing several cells, often near blood vessels (Fig 6B). In both these nevus types, melanocytes arranged in small nests or as single cells may also be seen higher in the epidermis, but the architecture of the stratum corneum, granulosum, spinosum, and basal cell layer remains otherwise unchanged and as previously described for normal epidermis. This is in contrast to dysplastic nevi, which show focal loss of the cell-cell keratinocyte borders at the dermo-epidermal junction and fine bright granules within the epidermis that probably represent melanin bodies (Fig 6C). Dysplastic nevi also show a greater variety in nevomelanocyte size and shape although cells still tend to be rounded or oval rather than dendritic (Fig 6D).

Malignant Melanoma

Pigmented melanomas imaged with RCM show the presence of pleomorphic bright cells within the epidermis and dermis.³⁴ These cells may be stellate in shape and possess coarse branching dendritic processes and eccentrically placed large nuclei (Fig 7).^{34,36,37} There is also disruption of the regular honeycombing architectural pattern of the stratum spinosum, with indistinct cell borders and bright grainy particles, probably melanin, distributed within the epidermis. Criteria to enable accurate differentiation of benign and malignant pigmented lesions need to be further defined, developed, and tested in large blinded studies although it currently appears that it is not difficult to distinguish between benign nevi vs. atypical or malignant melanocytic lesions. Interestingly, some features of melanomas can also be identified in amelanotic melanomas using RCM. Two cases have been reported in the literature, and it appears that it is possible to detect melanocytes in a clinically amelanotic tumor, presumably because of the presence of some melanin in premelanosomes.³⁶ Images from these patients showed the presence of bright round, oval, or fusiform cells, sometimes with dendritic processes. These cells were present either singly around the dermo-epidermal junction and spinous layer, or in confluent ill-defined groups. As with mela-

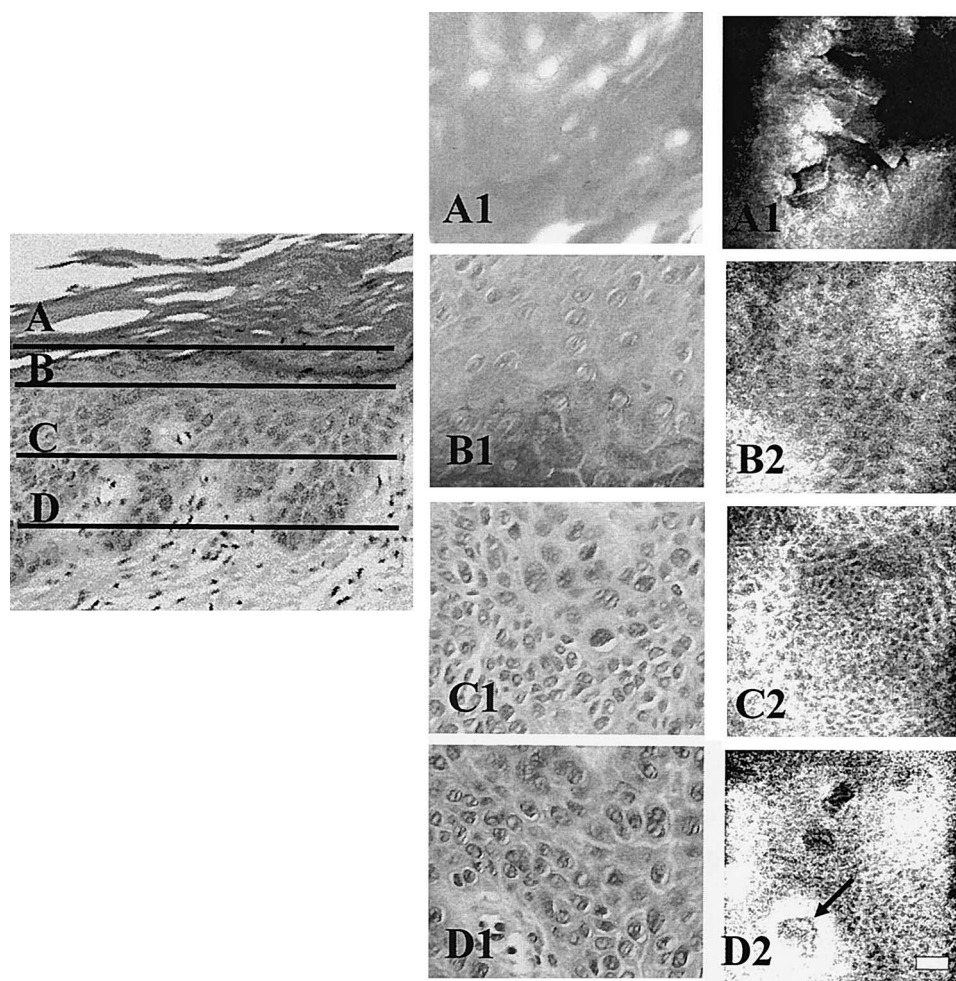


Figure 5. Vertical H&E section of actinic keratosis. Lines represent depths in the epidermis corresponding to horizontal sections. Left column corresponds to en face conventional histopathology while right column corresponds to confocal images. A, Stratum corneum showing irregular hyperkeratosis (*). B, Stratum granulosum demonstrates uniform, evenly spaced, broad keratinocytes. C, Stratum spinosum shows enlarged, pleomorphic nuclei with haphazard orientation. D, Stratum basale shows enlarged, pleomorphic nuclei with haphazard orientation. Dermal papillae appear as well-demarcated, dark holes in epidermis (arrow), containing blood vessels. (30 \times , 0.9 NA water immersion objective lens; scale bar 25 μ m). Source: Agasshi D, Anderson RR, González S. Confocal laser microscopic imaging of actinic keratoses in vivo: a preliminary report. *J Am Acad Dermatol* 2000;43:42-8. Reprinted by permission of Mosby, Inc.

notic melanomas, there was architectural disruption and loss of distinct cell borders. These RCM features correlated well with conventional histology. It remains to be seen whether malignant cells with small amounts of pigment can be accurately identified. Further studies are being performed to clarify this.

Use of Reflectance Confocal Microscopy as Adjunct to Standard Therapy

Margin Assessment and Adjunct to Surgery

The ability of RCM to perform noninvasive evaluation of skin lesions means that it has the potential to define lesion margins before surgical or nonsurgical therapy. This could be particularly helpful in margin assessment of tumors with radial growth phases, including lentigo maligna melanomas or some basal cell carcinomas, or

tumors that are difficult to see clinically, such as amelanotic melanomas or sclerosing infiltrative basal cell carcinomas. The main limiting factor to date has been the limited depth of penetration, which prevents accurate imaging at depths below the superficial dermis. Lack of contrast can also pose a problem, which might be solved by the future development of exogenous contrast agents. Despite present limitations, RCM can help identify areas that are atypical and need biopsy to provide histologic confirmation.

RCM may aid in the rapid establishment of tumor margins by examining excised specimens during procedures such as Mohs' micrographic surgery. With RCM of ex vivo unprocessed tissue, it is possible to detect neoplastic cells by using 5% acetic acid and cross-polarized illumination.³⁸ This technique makes the neo-

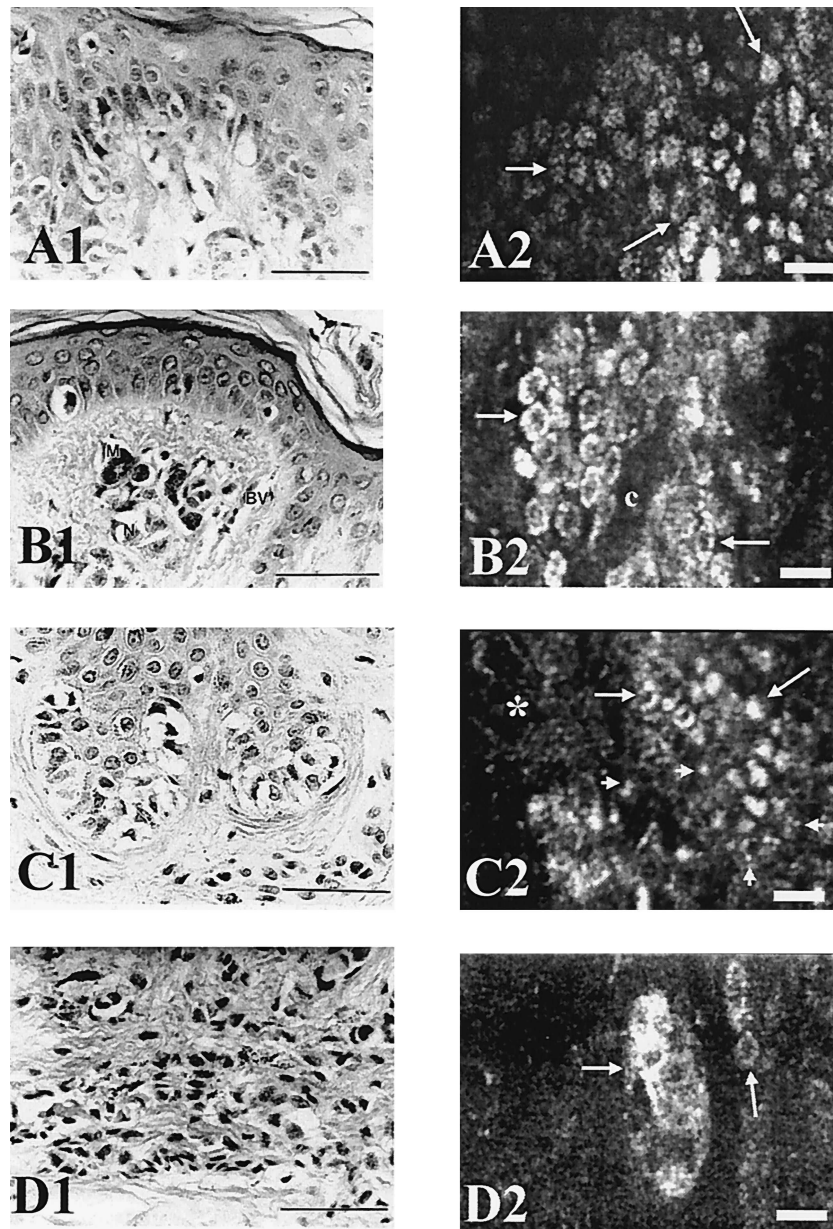


Figure 6. Confocal images of benign and dysplastic nevi. A1 corresponds to histologic section of a melanocytic nevus showing melanocytes and keratinocytes in the basal layer. A2 corresponds to en face section of a benign nevus showing an uniform pattern of bright monomorphic cells (arrows) and pigmented basal keratinocytes. B1 corresponds to histologic section of a compound nevus demonstrating blood vessels (BV), nevomelanocytes (N) and melanophages (M). B2 corresponds to en face section of the same compound nevus showing nests of bright monomorphous cells (arrows). Dermal location of these nests can be determined by identification of the blood vessels (labeled c). C1 corresponds to histologic section of a lentiginous compound dysplastic nevus. Note nest of nevomelanocytes at the dermoepidermal junction showing uniform cytoplasm and nuclei but variation in size. C2 Nevomelanocytes can be identified by their bright, highly refractive nature (arrows). In comparison to common melanocytic nevi, the dysplastic nevi have more variation in their size and less brightness. Asterisks indicate focal loss of keratinocyte borders. Melanin dusts also can be noted (arrowheads). D1 corresponds to histologic section of a lentiginous compound dysplastic nevus showing the dermal component. Note variation in melanin content. D2 Nest of nevomelanocytes in the papillary dermis (arrows). (A1, B1, C1, and D1, H&E-stained sections, scale bar 50 μm ; A2, B2, C2 and D2, in vivo confocal images 100 \times , 1.2 NA water immersion objective lens; scale bar, 25 μm) Source: Langley RGB, Rajadhyaksha M, Dwyer PJ, et al. Confocal scanning laser microscopy of benign and malignant melanocytic skin lesions in vivo. *J. Am Acad Dermatol* 2001; 45: 365-76. Reprinted by permission of Mosby, Inc.

plastic nuclei bright and surrounding dermis dark. It has been demonstrated recently that it is thereby possible to examine nonmelanoma skin cancers in ex vivo tissue during Mohs' micrographic surgery without fro-

zen sections. This offers the advantage of rapid visualization of margins compared to permanent sectioning and the ability to do special stains or permanent stains in areas that are equivocal. RCM has also been used

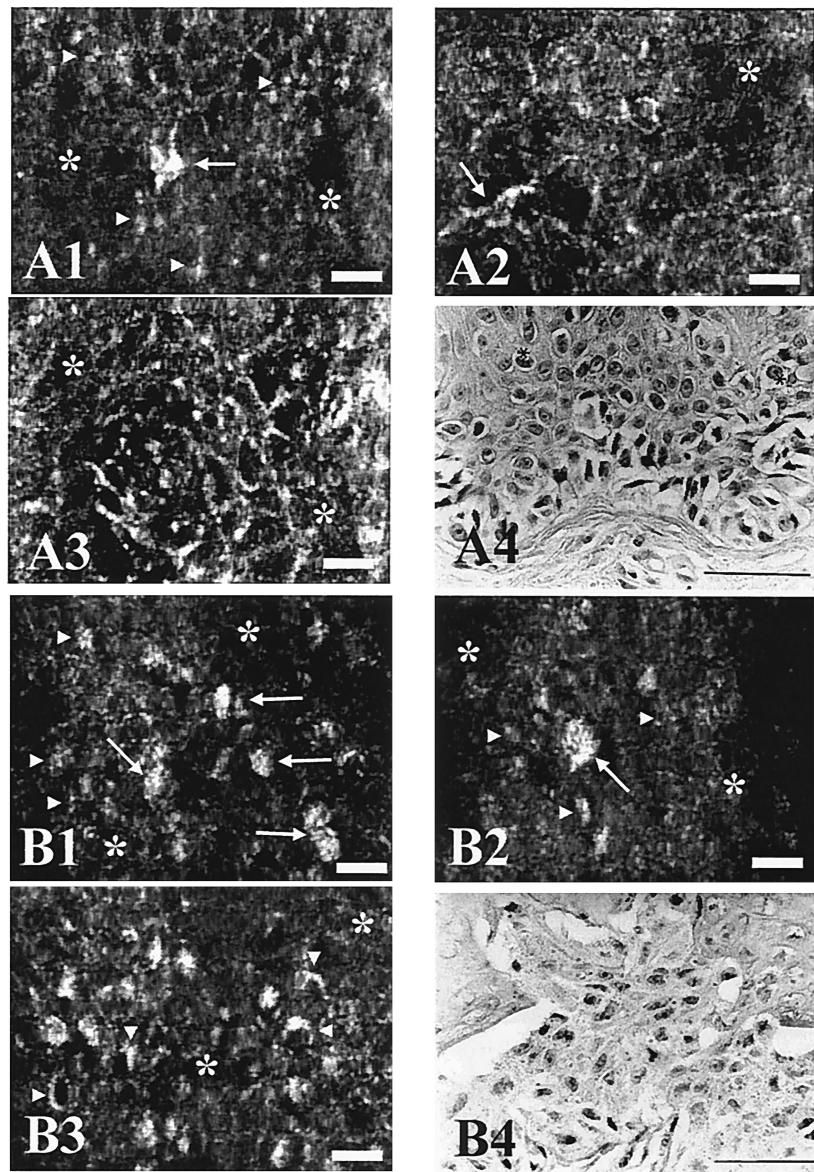


Figure 7. Confocal images of melanoma. A1-A3, Confocal images of a superficial spreading malignant melanoma. Loss of keratinocyte border (asterisk in A1-A3); bright granular highly refractile particles (arrowheads in A1); and atypical stellate cells (arrows A1 and A2) are seen. A4, Histologic section of intraepidermal component of superficial spreading malignant melanoma showing confluence of tumor cells at dermoepidermal junction as well as individual cells of varying levels of the epidermis, so-called "pagetoid" spread (asterisks). B1-B3, Confocal images of a melanoma in situ. Focal disappearance of keratinocyte cell borders (asterisks in B1-B3), presence of individual polymorphic cells (arrows in B1, B2) and fine granular particules (arrowheads in B1, B2) can be identified. Note eccentric melanin staining (arrowheads in B3). B4, Histologic section of malignant melanoma in situ, superficial spreading type. Note confluent nest of markedly atypical tumor cells with varying quantities of melanin in their cytoplasm. (A1-A3 and B1-B3, in vivo confocal images 100 \times , 1.2 NA water immersion objective lens; scale bar, 25 μ m; A4 and B4, H&E-stained sections, scale bar 50 μ m). Source: Langley RGB, Rajadhyaksha M, Dwyer PJ, et al. Confocal scanning laser microscopy of benign and malignant melanocytic skin lesions in vivo. *J. Am Acad Dermatol* 2001; 45:365-76. Reprinted by permission of Mosby, Inc.

effectively in vivo during Mohs surgery to help locate tumor and rapidly visualize the margins for BCC and melanoma. However, poor visualization of non-flat wounds, wound fluid interference, and limited wavelength penetration make it impractical to use RCM at this time in vivo for Mohs surgery. Yet, the recent observation that aluminum chloride solution enhances visualization of malignant BCC cells in vivo together

with upcoming technical refinements in RCM may make it easier to overcome some of these difficulties.³⁹

Use of Confocal Reflectance Microscopy for Evaluating Response to Treatment

To assess histologic changes that occur after new treatments, a biopsy would normally be required. If a

treated lesion was small, this might only be possible once. Unlike surgical tissue sampling such as a biopsy, it is possible to repeat RCM on the same skin lesion or site repeatedly. This permits evaluation of dynamic processes such as response to therapy. As an example of this, RCM monitoring of the response to laser treatment of cherry angiomas has been reported.¹⁴ This showed that several minutes after treatment with pulsed dye laser, blood flow within the lesions ceased and was replaced by amorphous cords of brightly refractile material. There followed an early inflammatory cell infiltrate, which gradually disappeared, and the development of new small vessels, so that by 3 weeks after treatment, normal epidermis and dermis replaced the lesion. It was also shown that the effect of a different laser, the krypton laser, was slightly different, with no amorphous cord development but only dark spaces, epidermal necrosis as an early event, and healing and normalization of architecture seen by 4 weeks after treatment. There are ongoing RCM studies evaluating the histopathological responses of actinic keratoses treated with 5-aminolevulinic acid photodynamic therapy, as well as those of basal cell carcinomas treated with imiquimod. To date, RCM has proven to be accurate in establishing the presence of BCC before treatment and responsiveness of the BCC to the treatment regimen with imiquimod.³¹

Difficulties and Potential Solutions

Although we have discussed several of the benefits there are to using RCM, there are some limitations. The microscopes themselves are available in only a minority of dermatology departments and require a learning curve to operate them and interpret the images. They are costly and cumbersome to use because of their size and articulation arms, as was similar to early lasers. This will undoubtedly change as it did for early lasers. Problems related to imaging include a depth of penetration limited to the superficial dermis, or even less, when a lesion is particularly hyperkeratotic. This might be improved by experimenting with different immersion media and illumination sources. The current contact device is also cumbersome and difficult to use on a nonflat surface.

Work is ongoing to facilitate the creation of vertical sections and three-dimensional sections, which would vastly increase the potential of RCM. There is also a portable prototype that will further miniaturize the microscope to produce a more portable or hand-held device, possibly using fiber optics. This would make it much more user friendly and practical.

Conclusions

RCM offers the potential to make a large contribution to the advancement of medical research and clinical care.

In research, it offers benefits both ex vivo and in vivo. Ex vivo it can allow us to sample tissue and noninvasively evaluate it to determine what further testing may be helpful on the same exact tissue. In vivo, RCM can be used to study normal processes or pathophysiologic processes noninvasively over time. It can also be used to establish the presence or absence of a dynamic immunologic event and guide tissue sampling such as fine needle aspiration for DNA analysis of a specific immunologic event. Likewise, with the advent of noninvasive therapies, noninvasive RCM can be used to establish timing and dosing responses to therapy.

Clinically, RCM has value both ex vivo and in vivo. Ex vivo tissue can first be evaluated with RCM, and when necessary, a specific finding can be confirmed on the same exact tissue using appropriate markers or stains. This is unlike current pathology processes, which often require the use of a similar or adjacent tissue but not the same exact tissue. In vivo, the potential is tremendous. How would our world change if we could noninvasively diagnose skin lesions and, with the advent of new minimally invasive therapies, effect treatment and noninvasively monitor that treatment?

The potential to advance medical care is obvious. Much like early x-ray imaging and ultrasound, RCM is in its infancy. It remains to be seen if the technical challenges can be overcome to let it realize a similar success. In the meantime, clinicians need to advance this body of knowledge so that we won't need to play catch up with the technical advances that should be expected as the laser boom continues.

Acknowledgments

This work was partially supported by National Institutes of Health NIOSH Grant RO1 OH04029 (to S.G.).

References

1. Tearney GT, Brezinski ME, Southern JF, et al. Determination of the refractive index of highly scattering human tissue by optical coherence tomography. *Opt Lett* 1995;20:2258-60.
2. Mansotti L. Basic principles and advanced technical aspects of ultrasound imaging. In: Guzzardi R, editor. *Physics and engineering of medical imaging*. Boston: Martinus Nijhoff Publishers, 1987:263-317.
3. Markisz JA, Aquilia MG. *Technical magnetic resonance imaging*. Stanford: Appleton & Lange, 1996.
4. New KC, Petroll WM, Boyde A, et al. In vivo imaging of human teeth and skin using real-time confocal microscopy. *Scanning* 1991;13:369-72.
5. Corcuff P, Leveque JL. In vivo vision of the human skin with the tandem scanning microscope. *Dermatology* 1993;186:50-4.
6. Rajadhyaksha M, Grossman M, Esterowitz D, et al. In vivo confocal scanning laser microscopy of human skin: melanin provides strong contrast. *J Invest Dermatol* 1995;104:946-52.

63
64
65
66
67
68
69
70
71
72
73
74
75
76
77
78
79
80
81
82
83
84
85
86
87
88
89
90
91
92
93
94
95
96
97
98
99
100
101
102
103
104
105
106
107
108
109
110
111
112
113
114
115
116
117
118
119
120
121
122

7. Minsky, M. Microscopy apparatus. U.S. Patent No. 3013467, 7 Nov. 1957.
8. Cavanagh HD, Jester JV, Essepian J, et al. Confocal microscopy of the living eye. *CLAO J* 1990;16(1):65-73.
9. Jester JV, Andrews PM, Petroll WM, et al. In vivo, real-time confocal imaging. *J Electron Microsc Technol* 1991; 18(1):50-60.
10. Andrews PM, Petroll WM, Cavanagh HD, et al. Tandem scanning confocal microscopy (TSCM) of normal and ischemic living kidneys. *Am J Anat* 1991;191(1):95-102.
11. Masters BR, Thaer AA. In vivo human corneal confocal microscopy of identical fields of subepithelial nerve plexus, basal epithelial, and wing cells at different times. *Microsc Res Tech* 1994;29(5):350-6.
12. Rajadhyaksha M, González S, Zavislan J, et al. In vivo confocal scanning laser microscopy of human skin II: advances in instrumentation and comparison to histology. *J Invest Dermatol* 1999;113:293-303.
13. González S, White WM, Rajadhyaksha M, et al. Confocal imaging of sebaceous gland hyperplasia in vivo to assess efficacy and mechanism of pulsed dye laser treatment. *Lasers Surg Med* 1999;25(1):8-12.
14. González S, Sackstein R, Anderson RR, et al. Real-time evidence of in vivo leukocyte trafficking in human skin by reflectance confocal microscopy. *J Invest Dermatol* 2001; 117(2):384-6.
15. Agasshi D, Anderson RR, González S. Time-sequence histologic imaging of laser-treated cherry angiomas using in vivo confocal microscopy. *J Am Acad Dermatol* 2000;43: 37-41.
16. Agasshi D, González E, Anderson RR, et al. Elucidating the pulsed dye laser treatment of sebaceous hyperplasia in vivo using real-time confocal scanning laser microscopy. *J Am Acad Dermatol* 2000;43:49-53.
17. Huzaira M, Rius F, Rajadhyaksha M, et al. Topographic variations in normal skin histology, as viewed by in vivo confocal microscopy. *J Invest Dermatol* 2001;116(6):846-52.
18. González S, Rajadhyaksha M, Rubinstein G, et al. Characterization of psoriasis in vivo by reflectance confocal microscopy. *J Med (J Med Clin Exper Mol)* 1999;30(5 and 6):337-356.
19. González S, Rajadhyaksha M, Anderson RR. Confocal imaging of proliferative cutaneous lesion margin in vivo. *J Invest Dermatol* 1998;111(3):538-9.
20. González S, González E, White WM, et al. Allergic contact dermatitis: correlation of in vivo confocal imaging to routine histology. *J Am Acad Dermatol* 1999;40:708-13.
21. Swindells, K, Burnett, N, Rius-Díaz, F, et al. Reflectance confocal microscopy may differentiate acute allergic and irritant contact dermatitis *in vivo* (Abstract). 63rd Annual Meeting of The Society for Investigative Dermatology 2002.
22. Marshall EK, Lynch V, Smith HW. On dichlorethylsulphide (mustard gas) II. Variations in susceptibility of the skin to dichlorethylsulphide. *J Pharm Exp Therap* 1919; 12:291-301.
23. Weigand DA, Gaylor JR. Irritant reaction in negro and caucasian skin. *South Med J* 1974;67(5):548-51.
24. Taylor SC. Skin of color: biology, structure, function, and implications for dermatologic disease. *J Am Acad Dermatol* 2002;46:S41-62.
25. Hicks, S, Swindells, K, Middelkamp-Hup, M, et al. Confocal histopathology of irritant contact dermatitis *in vivo* and the impact of skin color. *J Am Acad Dermatol*. In press.
26. Markus R, Huzaira M, Anderson RR, et al. A better KOH prep? In vivo diagnosis of tinea with confocal microscopy. *Arch Dermatol* 2001;137:1076-8.
27. Hongcharu W, Dwyer P, González S, et al. Confirmation of onychomycosis by confocal microscopy. *J Am Acad Dermatol* 2000;42:214-7.
28. González S, Rajadhyaksha M, González-Serva A, et al. Confocal reflectance imaging of folliculitis in vivo. Correlation of confocal imaging to routine histology. *J Cut Pathol* 1999;26:201-5.
29. González, S, Tannous, Z. Real-time in vivo confocal reflectance microscopy of basal cell carcinoma. *J Am Acad Dermatol*. In press.
30. Nori, S, Swindells, K, Rius Diaz, F, et al. Sensitivity and specificity of near infrared reflectance confocal scanning laser microscopy for *in vivo* diagnosis of basal cell carcinoma. (Abstract). 63rd Annual Meeting of The Society for Investigative Dermatology 2002.
31. Torres, A, Schanbacher, C, Marra, D, et al. Imiquimod 5% cream preceding surgery for BCC monitoring with confocal microscopy (Abstract). 20th World Congress of Dermatology.
32. Agasshi D, Anderson RR, González S. Confocal laser microscopic imaging of actinic keratoses in vivo: a preliminary report. *J Am Acad Dermatol* 2000;43:42-8.
33. Trehan, M, Swindells, K, Taylor, CR, et al. Confocal microscopy imaging of actinic keratoses post-photodynamic therapy with 5-ALA (Abstract). 20th World Congress of Dermatology.
34. Langley RGB, Rajadhyaksha M, Dwyer PJ, et al. confocal scanning laser microscopy of benign and malignant melanocytic skin lesions in vivo. *J Am Acad Dermatol* 2001;45: 365-76.
35. Busam KJ, Charles C, Lee G, et al. Morphologic features of melanocytes, pigmented keratinocytes, and melanophages by in vivo confocal scanning laser microscopy. *Mod Pathol* 2001;14(9):862-8.
36. Busam KJ, Hester K, Charles C, et al. Detection of clinically amelanotic malignant melanoma and assessment of its margins by in vivo confocal scanning laser microscopy. *Arch Dermatol* 2001;137(7):923-9.
37. Tannous Z, Mihnn M, Flotte T, et al. In vivo examination of lentigo maligna, in situ malignant melanoma, lentigo maligna type by near-infrared confocal microscopy: comparison of confocal images with histologic sections. *J Am Acad Dermatol*. 2002;46:260-3.
38. Rajadhyaksha M, Menaker G, Flotte T, et al. Confocal examination of non-melanoma cancers in skin excisions to potentially guide Mohs micrographic surgery without histopathology. *J Invest Dematol* 2001;117(5):1137-43.
39. Tannous Z, Torres A, González S: Real-time, in-vivo confocal reflectance microscopy, a surgical guide for Mohs micrographic surgery (Abstract). 20th World Congress of Dermatology.

AQ:2

AQ:3

AUTHOR QUERIES

AUTHOR PLEASE ANSWER ALL QUERIES

1

AQ1—AUTHOR: is there a page range for ref 3?

AQ2—AUTHOR: Please update ref. 25 if possible.

AQ3—AUTHOR: Please update ref. 29 if possible.
